

Advanced dry age-related macular degeneration (AMD) / Geographic Atrophy (GA)

Awareness

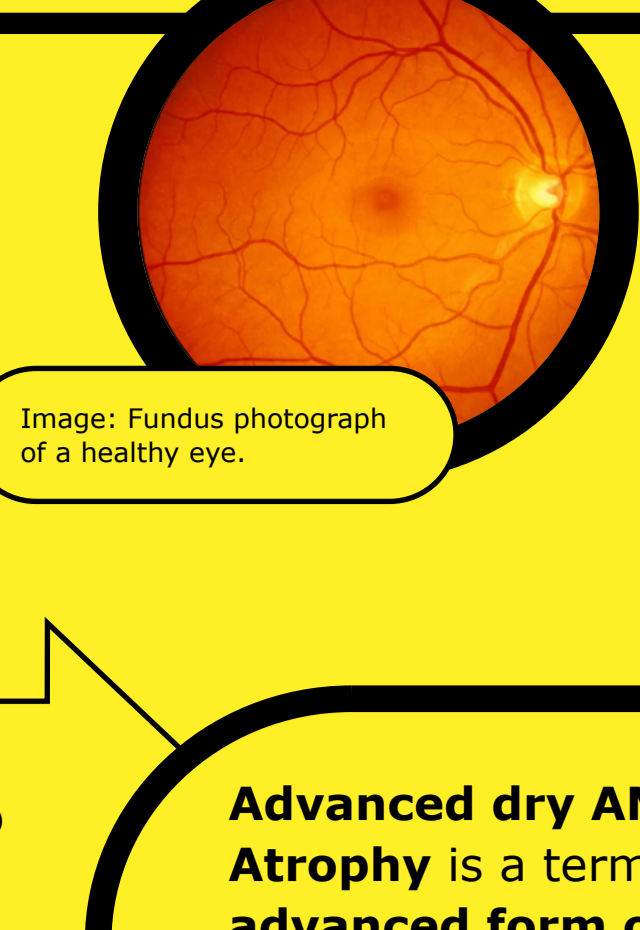


Image: Fundus photograph of a healthy eye.

Image: Fundus photograph of advanced dry AMD.

Advanced Dry AMD

Geographic Atrophy

Advanced dry AMD or Geographic Atrophy is a term used to describe the advanced form of dry age-related macular degeneration (AMD), is a progressive and irreversible disease affecting the macula, the central part of the retina.

5 million

Currently advanced dry AMD affects more than 5 million people worldwide. This number is expected to increase to more than 10 million by 2040.

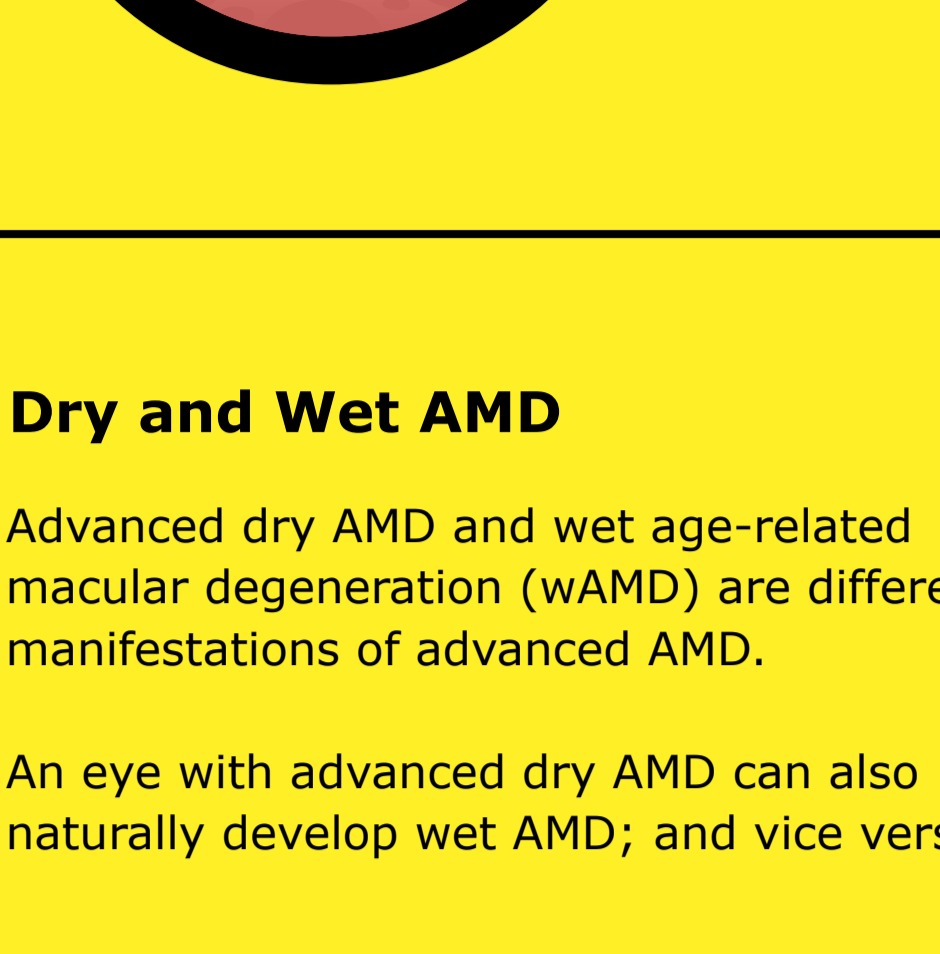
4x

From age 50, prevalence quadruples every 10 years.

20%

Advanced dry AMD accounts for up to 20% of all legal blindness attributed to AMD.

Advanced dry AMD is a chronic progressive degeneration of the **macula**, which is a central part of the **retina** that allows the eye to see accurate details for daily activities.



Retina

Macula

Drusen

i The retina contains millions of light-sensitive cells (rods and cones) that receive and organize visual information.

i The fovea at the center of the macula is a small pit that contains the largest concentration of cone cells thus provides greatest visual acuity.

i Drusen are small yellow deposits of fatty proteins (lipids) that accumulate under the retina. They can be used to grade the stage and severity of AMD.

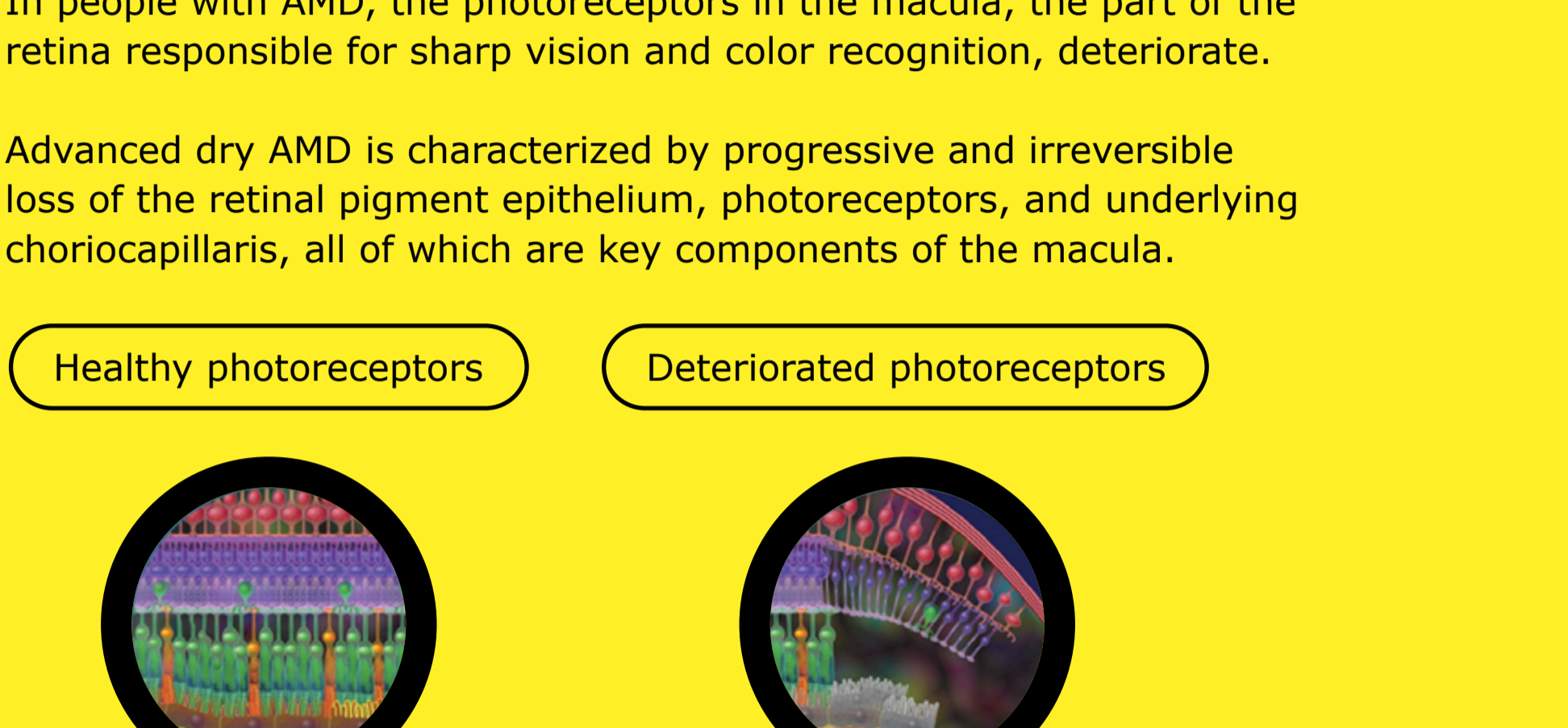
Dry and Wet AMD

Advanced dry AMD and wet age-related macular degeneration (wAMD) are different manifestations of advanced AMD.

An eye with advanced dry AMD can also naturally develop wet AMD; and vice versa.

98%

of patients with wet AMD progressed to advanced dry AMD over an average of 7.3 years of follow-up.



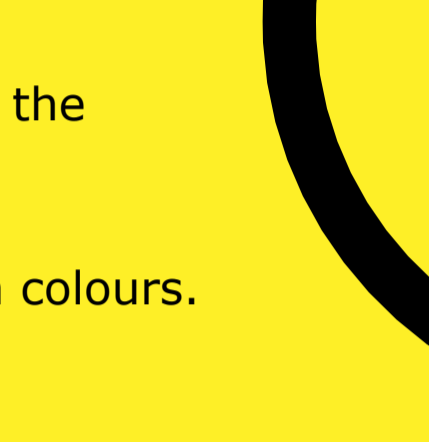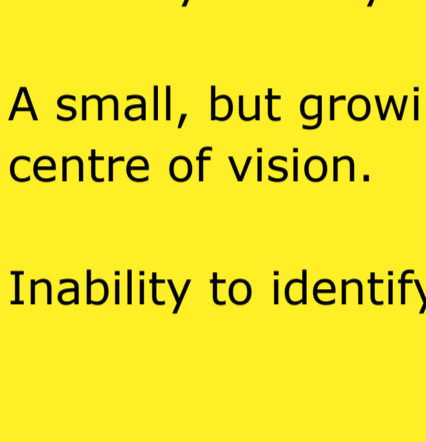
Causes

In people with AMD, the photoreceptors in the macula, the part of the retina responsible for sharp vision and color recognition, deteriorate.

Advanced dry AMD is characterized by progressive and irreversible loss of the retinal pigment epithelium, photoreceptors, and underlying choriocapillaris, all of which are key components of the macula.

Healthy photoreceptors

Deteriorated photoreceptors



Simplified image to illustrate healthy and deteriorated photoreceptors.

Signs and symptoms of advanced dry AMD may include:

- Hazy or blurred vision.
- Straight lines may appear crooked.
- An inability to see details closely, as well as difficulty identifying objects from a distance.
- A small, but growing, blind spot in the centre of vision.
- Inability to identify and distinguish colours.

50% of patients develop advanced dry AMD in both eyes within 7 years of initial diagnosis.

Risk factors associated with advanced dry AMD

Modifiable environmental risk factors

- **Smoking** tobacco and cigarettes increases the likelihood of developing advanced dry AMD.
- **Body Mass Index (BMI):** Individuals with a BMI of 30 and over are more susceptible to developing advanced dry AMD.
- **Fatty diets:** Consumption of foods high in cholesterol and fat can increase a person's glycemic index which causes disposition of adipose tissue in the blood vessels of the retina.
- **Usage of medications:** Certain medications have been linked with an increased risk of developing AMD. If you are taking any medication for other conditions you should discuss this with your healthcare professional.

Non-modifiable risk factors

- **Age:** There is an increased chance of being diagnosed with advanced dry AMD the older people become.
- **Genetics:** People with a family history are at a higher risk of developing the condition.
- **Ethnicity:** The prevalence of advanced dry AMD is highest among older people of Caucasian descent.

Diagnosis and disease progression

Disease progression

The most significant and central feature of developing advanced dry AMD is larger (>125 µm) or merging drusen as over 95% of patients with these features develop advanced dry AMD.

Non-central atrophy



Some loss of peripheral, peripheral low light vision. Patient only notes under certain conditions or through designed tests.

Growth of non-central atrophy



Loss of peripheral, low light vision.

Beginning to affect fovea



Loss of peripheral, low vision; patches of lost central vision.

Severe central atrophy



Loss of central vision leading to blindness.

While lesion growth in advanced dry AMD may appear to proceed slowly, disease progression is constant and irreversible.

Diagnosis

Advanced dry AMD can be diagnosed and monitored by an ophthalmologist, retinal specialist or optometrist.

Retinal imaging techniques are used to identify, diagnose and monitor all stages of AMD, including advanced dry AMD. When diagnosing and monitoring AMD, your eye doctor will look for the following features in the retina by applying ophthalmoscopy or on fundus photo. This may include:

- Decorated with drusen.
- A sharply demarcated area in the macular region with an atrophic retina, lacking pigmentation.
- Visible underlying choroidal blood vessels.

Ways to diagnose

Fundus autofluorescence angiography imaging is currently a standard imaging technology to visualize the retinal pigment epithelium (RPE) in advanced dry AMD.



Image: Normal fundus autofluorescence of a retina

Optical coherence tomography (OCT): The atrophy of the retinal layers can be clearly seen with this non-invasive imaging technique.



Image: Horizontal OCT scan over the fovea

- While lesion growth in advanced dry AMD may appear to proceed slowly, disease progression is often constant and irreversible.
- Progression can be highly variable, it typically takes several years from the onset of advanced dry AMD to cause consistent deficits in vision.
- This is because the fovea, which is responsible for central vision and visual acuity, may be spared until advanced dry AMD is very advanced.
- However even before the fovea is affected by advanced dry AMD, lesion growth is already affecting functional vision.

Treatment

Treatment of advanced dry AMD

To date, there are no approved therapies to reduce the rate of advanced dry AMD progression, although several potential therapies are under investigation.

How to best manage advanced dry AMD

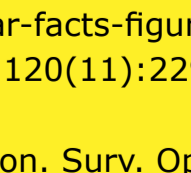
- **Regular eye examinations** Progression of advanced dry AMD may be managed through regular eye examinations and early detection of the retinal changes.
- **Visual rehabilitation** In addition to regular eye examinations, the disease can and low vision aids through visual rehabilitation with the use of magnifiers and low vision aids.
- **Lifestyle modification** Some simple approaches that can help prevent or slow the progression advanced dry AMD include:
 - Stop smoking
 - Exercising to reduce BMI
 - Eating foods low in cholesterol
 - Intake of antioxidants & vitamins such as vitamin C, vitamin E, beta-carotene and zinc

Overview of treatment strategies under investigation

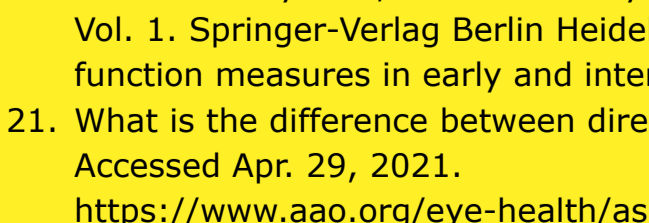
- Modulating the visual cycle to reduce the accumulation of toxic byproducts
- Reducing or inhibiting drusen formation
- Complement inhibition to regulate an overactive complement system
- Improving blood flow in the choroid
- Reducing or eliminating oxidative stress
- Reducing or eliminating inflammation
- Replacing, repairing, or regenerating lost RPE cells and photoreceptors
- Cell therapy

More information

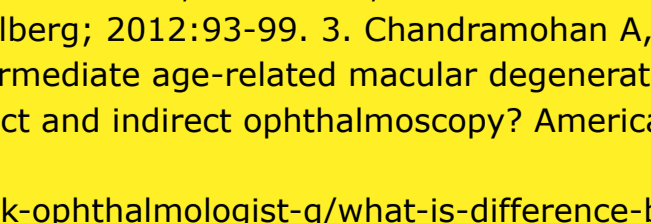
For more information visit dryAMD.eu



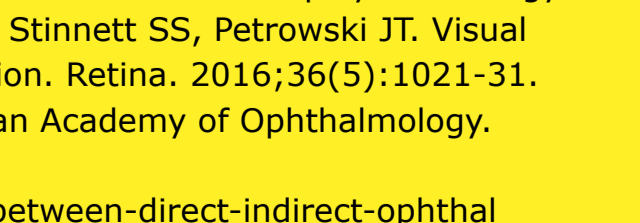
How vision works



Advanced forms of AMD



Glossary



LEARN MORE

LEARN MORE

LEARN MORE

This infographic about advanced dry AMD is not a diagnosis tool. Please consult a healthcare professional if you believe you are suffering from AMD.

References

1. Gehrs KM, et al. Ann Med. 2006;38(7):450-471.
2. Fleckenstein M, et al. Ophthalmology. 2018;125:369-390.
3. Wong WL, et al. Lancet Glob Health. 2014;2:e106-116.
4. Rudnicka AR, et al. Ophthalmology. 2012;119:571-580.
5. Biarnés M, et al. Optom Vis Sci. 2011;88(7):881-889. 11
6. Fleckenstein, M. et al. The progression of geographic atrophy secondary to age-related macular degeneration. Ophthalmology 125, 369–390 (2018).
7. Bear, M., Connors, B. & Paradiso, M. Neuroscience: Exploring the Brain (Third Edition). Library (Lond). (2006) doi:10.1007/97802234670.
8. Mitchell, P., Liew, G., Gopinath, B. & Wong, T. Y. Age-related macular degeneration. www.thelancet.com vol. 392 www.thelancet.com (2018).
9. Remington, L. A. Aqueous and Vitreous Humors. In Clinical Anatomy and Physiology of the Visual System 109–122 (Elsevier Health Sciences, 2012). doi:10.1016/b978-1-4377-1926-0.10006-2.
10. Klein, R. et al. The Wisconsin Age-related Maculopathy Grading System. Ophthalmology 98, 1128–1134 (1991).
11. Age-Related Macular Degeneration: Facts & Figures. Bright Focus Foundation. Accessed Apr. 29, 2021. <https://www.brightfocus.org/macular/article/age-related-macular-facts-figures>
12. Rofagha S, et al, SEVEN-UP Study Group. Ophthalmology. 2013;120(11):2292-2299.
13. Ferris FL 3rd, et al. Ophthalmology. 2013;120(4):844-851.
14. Young, R. W. Pathophysiology of age-related macular degeneration. Surv. Ophthalmol. 31, (1987).
15. Boyer, D. S., Schmidt-Erfurth, U., Van Lookeren Campagne, M., Henry, E. C. & Brittain, C. The pathophysiology of geographic atrophy secondary to age-related macular degeneration and the complement pathway as a therapeutic target. Retina 37, 819–835 (2017).
16. Geographic Atrophy. Eye See You. Accessed Apr. 29, 2021. <https://eyeseeyou.care/en/geographic-atrophy/>
17. Sunness JS, et al. Ophthalmology. 2007;114(2):271-277.
18. Holz FG, et al. Ophthalmology. 2014;121(5):1079-1091.
19. Lindblad AS, et al. Arch Ophthalmol. 2009;127(9):1168-1174.
20. Lakshminarayana, V. Visual acuity. In: Chen J, Cranton W, Fihn M eds. Handbook of Visual Display Technology. Vol. 1. Springer-Verlag Berlin Heidelberg; 2012:93-99. 3. Chandramohan A, Stinnett SS, Petrowski JT. Visual function measures in early and intermediate age-related macular degeneration. Retina. 2016;36(5):1021-31.
21. What is the difference between direct and indirect ophthalmoscopy? American Academy of Ophthalmology. Accessed Apr. 29, 2021. <https://www.aao.org/eye-health/ask-ophthalmologist-q/what-is-difference-between-direct-indirect-ophthal>
22. Geographic Atrophy. EyeWiki. Accessed Apr. 29, 2021. https://eyewiki.aao.org/Geographic_Atrophy
23. Townsend WD. Scleral depression. Optom Clin. 1992; 2(3):127-44 (1992).
24. Ferguson LR, Grover S, Dominguez II JM, Balaiya S, Chalam KV. Retinal thickness measurement obtained with spectral domain optical coherence tomography assisted optical biopsy accurately correlates with ex vivo histology. PLoS ONE. 2014;9(10), e111203.
25. What Is Optical Coherence Tomography? American Academy of Ophthalmology. Accessed Apr. 29, 2021. <https://www.aao.org/eye-health/treatments/what-is-optical-coherence-tomography>.
26. Buschini, E. et al. Recent developments in the management of dry age-related macular degeneration. Clinical Ophthalmology vol. 9 563–574 (2015).
27. Bishop, P., Fekrat, S. & Chakravarthy, U. BMJ Best Practice: Age-related macular degeneration. Br. Med. J. (2018) doi:10.1016/S0140-6736(18)31550-2.

Apellis

© 2021 Apellis Switzerland GmbH. All rights reserved. This infographic is intended for an audience outside the United States. EU-GA-2100008

Visit www.dryAMD.eu for more information