

# Geographic atrophy (GA), an advanced form of age-related macular degeneration (AMD)

## Awareness

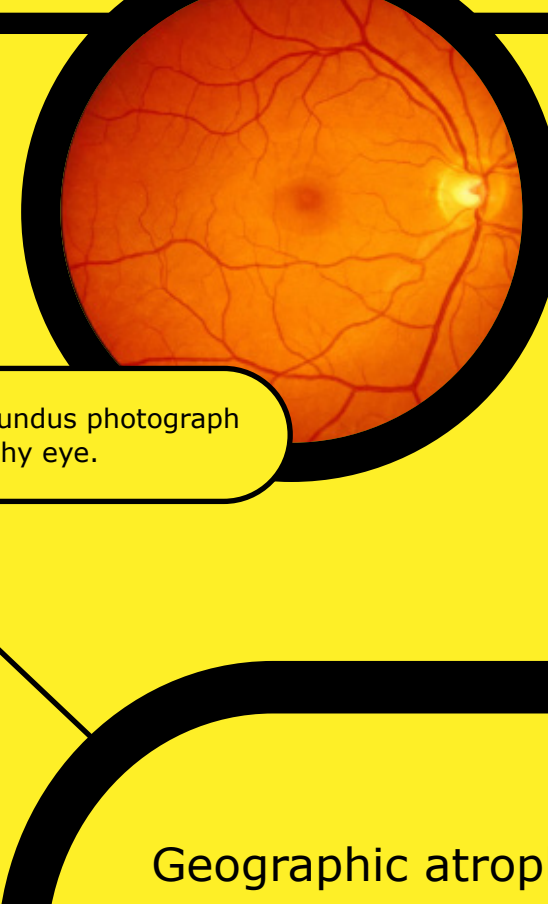


Image: Fundus photograph of a healthy eye.

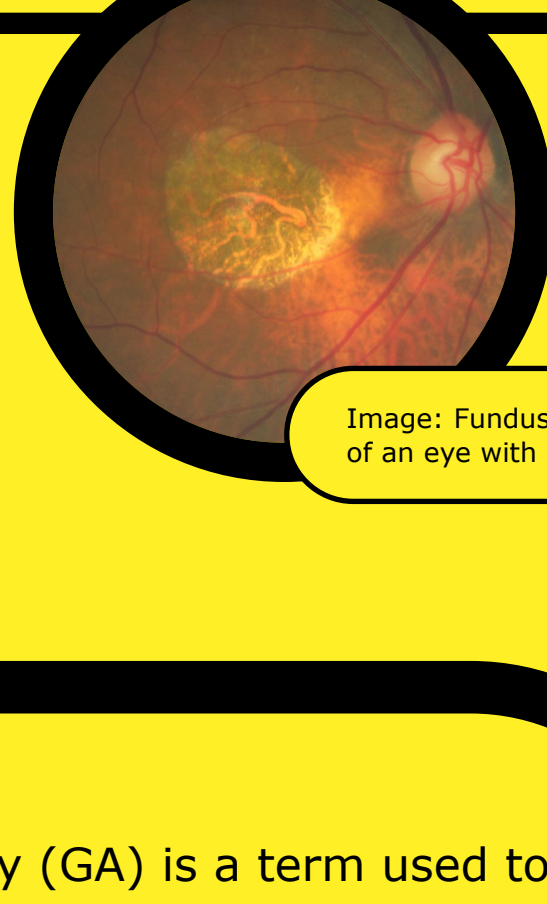


Image: Fundus photograph of an eye with GA.

### Geographic atrophy

### An advanced form of AMD

Geographic atrophy (GA) is a term used to describe an advanced form of AMD, a progressive and irreversible disease affecting the macula, the central part of the retina.<sup>1,2</sup>

**5 million**

Currently GA affects more than 5 million people worldwide. This number is expected to increase to more than 18 million by 2040.<sup>3</sup>

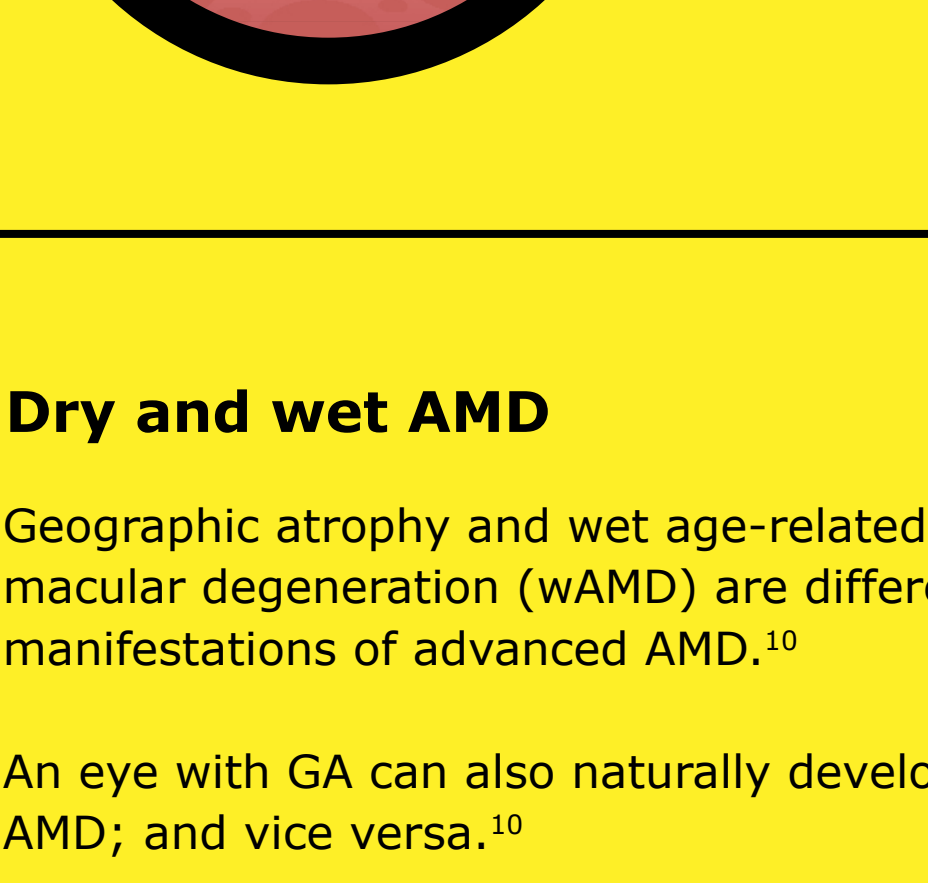
**4x**

From the age of 50, its prevalence quadruples every 10 years.<sup>4</sup>

**20%**

Geographic atrophy accounts for up to 20% of all legal vision loss attributed to AMD.<sup>1,5</sup>

GA is a chronic progressive degeneration<sup>2</sup> of the **macula**, which is a central part of the **retina** that allows the eye to see accurate details for daily activities.<sup>6,7</sup>

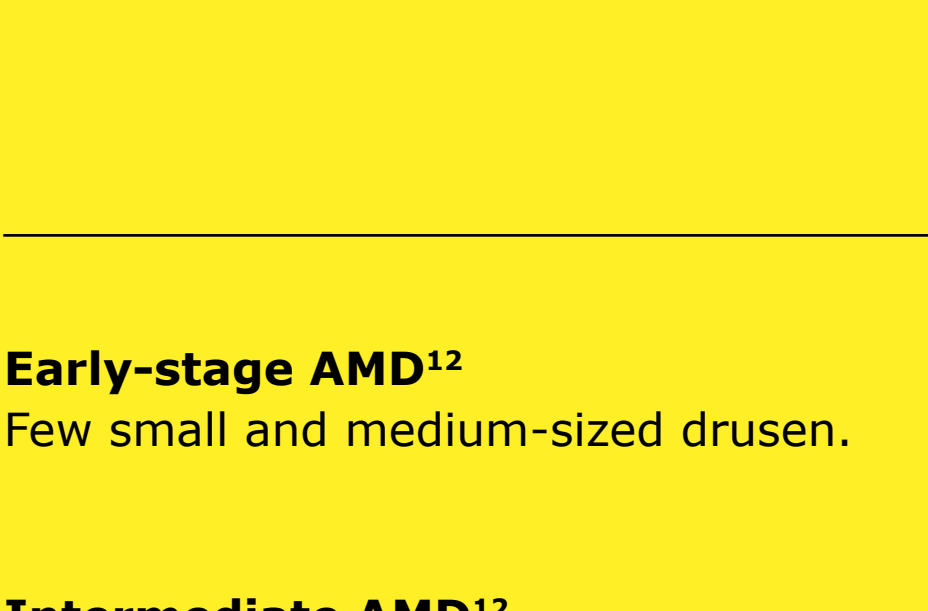


**Retina**

**Macula**

**i** The retina contains millions of light-sensitive cells (rods and cones) that receive and organise visual information.<sup>6</sup>

**i** The fovea at the centre of the macula is a small pit that contains the largest concentration of cone cells and thus providing the greatest visual acuity.<sup>8</sup>



**Drusen**

**i** Drusen are small yellow deposits of fatty proteins (lipids) that accumulate under the retina. They can be used to grade the stage and severity of AMD.<sup>9</sup>

## Dry and wet AMD

Geographic atrophy and wet age-related macular degeneration (wAMD) are different manifestations of advanced AMD.<sup>10</sup>

An eye with GA can also naturally develop wet AMD; and vice versa.<sup>10</sup>

**98%**

of patients with wet AMD progressed to geographic atrophy over an average of 7.3 years of follow-up.<sup>11</sup>

### Early-stage AMD<sup>12</sup>

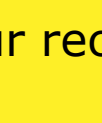
Few small and medium-sized drusen.



**196 million**<sup>10</sup>

### Intermediate AMD<sup>12</sup>

Medium-sized drusen or one large drusen.



### Advanced AMD<sup>8</sup>

Multiple large drusen.

**Advanced form of AMD, or geographic atrophy**

**Neovascular or wet AMD**

**5 million with GA**<sup>3</sup>

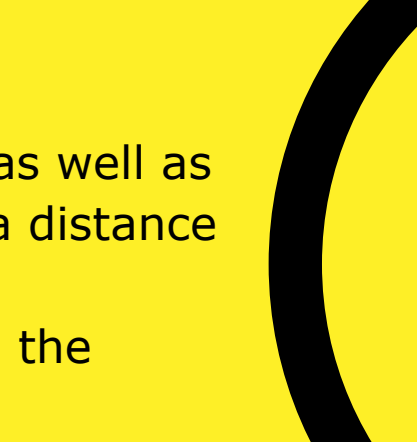
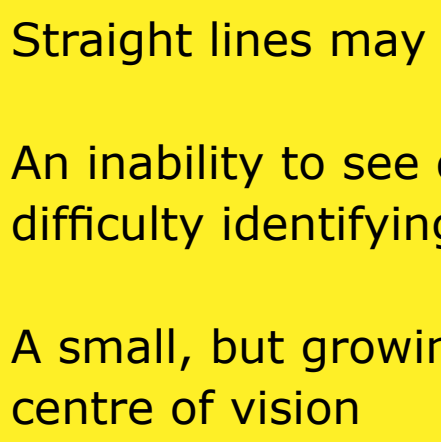
## Causes

In people with AMD, the photoreceptors in the macula, the part of the retina responsible for sharp vision and colour recognition, deteriorate.<sup>13</sup>

Geographic atrophy is characterised by progressive and irreversible loss of the retinal pigment epithelium (RPE), photoreceptors, and underlying choriocapillaris, all of which are key components of the macula.<sup>2,14</sup>

Healthy photoreceptors

Deteriorated photoreceptors



Simplified image to illustrate healthy and deteriorated photoreceptors.

## Signs and symptoms of geographic atrophy may include:<sup>15</sup>

- Hazy or blurred vision
- Straight lines may appear crooked
- An inability to see details closely, as well as difficulty identifying objects from a distance
- A small, but growing, blind spot in the centre of vision
- Inability to identify and distinguish colours

**50%**

of patients develop geographic atrophy in both eyes within 7 years of initial diagnosis.<sup>14</sup>

## Risk factors associated with geographic atrophy<sup>15</sup>

### Modifiable environmental risk factors

**Smoking** tobacco and cigarettes increases the likelihood of developing GA

**Body mass index (BMI):** Individuals with a BMI of 30+ are more susceptible to developing GA

**Fatty diets:** Consumption of foods high in cholesterol and fat can increase a person's glycaemic index, which causes deposition of adipose tissue in the blood vessels of the retina

**Usage of medications:** Certain medications have been linked with an increased risk of developing AMD. If you are taking any medication for other conditions you should discuss this with your healthcare professional

### Non-modifiable risk factors

**Age:** There is an increased chance of being diagnosed with GA the older people become

**Genetics:** People with a family history of AMD are at a higher risk of developing the condition

**Ethnicity:** The prevalence of GA is highest amongst older people of Caucasian descent

## Diagnosis and disease progression

### Disease progression

The most predictive and central feature of developing geographic atrophy (GA) is larger (>125 µm) or merging drusen, as over 95% of patients with these features develop GA.<sup>14</sup>

#### Non-central atrophy



Some loss of peripheral low light vision. Patient only notes under certain conditions or through designed tests.

#### Growth of non-central atrophy



Loss of peripheral, low light vision.

#### Beginning to affect fovea



Includes loss of peripheral, low light vision; patches of lost central vision.

#### Severe central atrophy



Loss of central vision leading to vision loss.

While lesion growth in GA may appear to proceed slowly, disease progression is constant and irreversible.<sup>14,16-18</sup>

## Diagnosis

Geographic atrophy (GA) can be diagnosed and monitored by an ophthalmologist, retinal specialist or optometrist.<sup>19</sup>

Retinal imaging techniques are used to identify, diagnose and monitor all stages of AMD, including advanced AMD. When diagnosing and monitoring AMD, your doctor will look for the following features in the retina by applying ophthalmoscopy or on fundus photo.<sup>20,21</sup>

- Build-up of drusen
- A sharply demarcated area in the macular region with an atrophic retina, lacking pigmentation
- Visible underlying choroidal blood vessels

## Ways to diagnose

**Fundus autofluorescence angiography** imaging is currently a standard imaging technology to visualise the retinal pigment epithelium in geographic atrophy (GA).<sup>22</sup>



Image: Normal fundus autofluorescence of a retina.

**Optical coherence tomography (OCT):** The atrophy of the retinal layers can be clearly seen with this non-invasive imaging technique.<sup>23,24</sup>



Image: Horizontal OCT scan over the fovea.

- While lesion growth in GA may appear to proceed slowly, disease progression is often constant and irreversible.<sup>14,16</sup>
- Progression can be highly variable; it typically takes several years from the onset of GA to cause consistent deficits in vision.<sup>25</sup>
- This is because the fovea, which is responsible for central vision and visual acuity, may be spared until GA is very advanced.<sup>25</sup>
- However, even before the fovea is affected by GA, lesion growth is already affecting functional vision.<sup>9,14</sup>

## Treatment

### Treatment of geographic atrophy

Though there are currently no approved therapies to reduce geographic atrophy (GA) progression, several potential medicines under investigation.<sup>15</sup>

### How to best manage geographic atrophy<sup>15</sup>

- **Regular eye examinations**  
Progression of geographic atrophy may be managed through regular eye examinations and early detection of the retinal changes.
- **Visual rehabilitation**  
In addition to regular eye examinations, the disease can also be managed through visual rehabilitation with the use of magnifiers and low vision aids.

### Lifestyle modification<sup>15,26</sup>

Some simple approaches that can help prevent or slow the progression of GA include:

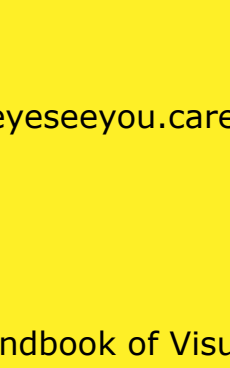
- Quitting smoking
- Exercising to reduce BMI
- Eating foods low in cholesterol
- Intake of antioxidants and vitamins such as vitamin C, vitamin E, beta-carotene and zinc

### Overview of treatment strategies under investigation<sup>25</sup>

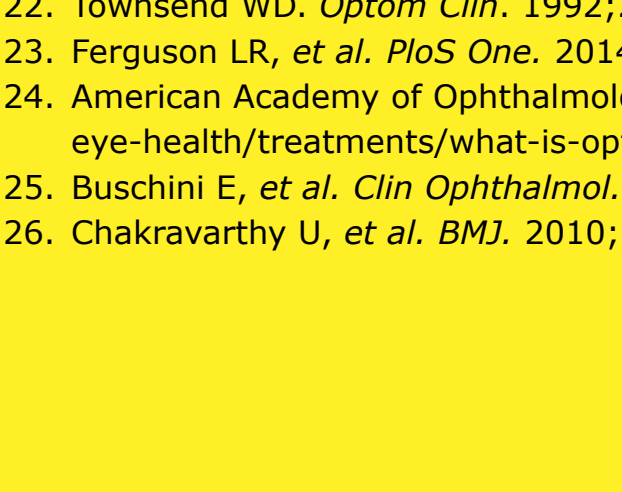
- Modulating the visual cycle to reduce the accumulation of toxic byproducts
- Reducing or inhibiting drusen formation
- Complement inhibition to regulate an overactive complement system
- Improving blood flow in the choroid
- Reducing or eliminating oxidative stress
- Reducing or eliminating inflammation
- Replacing, repairing, or regenerating lost RPE cells and photoreceptors
- Cell therapy

## More information

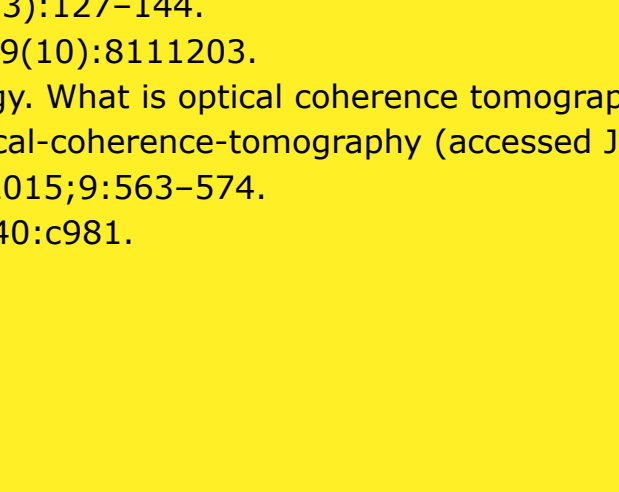
For more information visit [dryAMD.eu](https://www.dryAMD.eu)



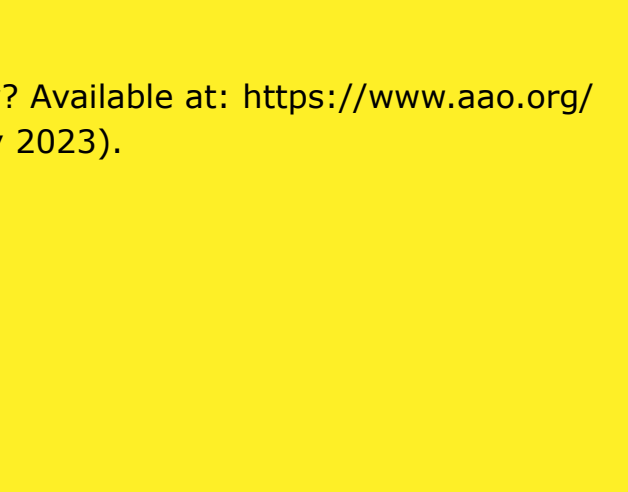
### How vision works



### Advanced forms of AMD



### Glossary



[LEARN MORE](#)

[LEARN MORE](#)

[LEARN MORE](#)

This infographic about geographic atrophy is not a diagnosis tool. Please consult a healthcare professional if you believe you are suffering from AMD.

## References

1. Gehrs KM, et al. *Ann Med.* 2006;38(7):450-471.
2. Fleckenstein M, et al. *Ophthalmology.* 2018;125:369-390.
3. Wong WL, et al. *Lancet Glob Health.* 2014;2:e106-116.
4. Rudnicka AR, et al. *Ophthalmology.* 2012;119(3):571-580.
5. Biamés M, et al. *Optom Vis Sci.* 2011;88(7):881-889.
6. Bear M, et al. *Neuroscience: Exploring the brain.* 3rd ed. London; 2006.
7. Mitchell P, et al. *Lancet.* 2018;392(10153):1147-1159.
8. Remington LA. Aqueous and vitreous humours. In: *Clinical Anatomy and Physiology of the Visual System.* 3rd ed. Elsevier Health Science; 2012.
9. Klein R, et al. *Ophthalmology.* 1991;98(7):1128-1134.
10. BrightFocus Foundation. Age-related macular degeneration: Facts and figures. Available at: <https://www.brightfocus.org/macular/article/age-related-macular-facts-figures> (accessed July 2023).
11. Rofagha S, et al. *Ophthalmology.* 2013;120(11):2292-2299.
12. Ferris FL 3rd, et al. *Ophthalmology.* 2013;120(4):844-851.
13. Young RW. *Surv Ophthalmol.* 1987;31(5):291-306.
14. Boyer DS, et al. *Retina.* 2017;37(5):819-835.
15. Eye See You. Geographic atrophy. 2021. Available at: <https://eyeseeyou.care/en/geographic-atrophy/> (accessed July 2023).
16. Sunness JS, et al. *Ophthalmology.* 2007;114(2):271-277.
17. Holz FG, et al. *Ophthalmology.* 2014;121(5):1079-1091.
18. Lindblad AS, et al. *Arch Ophthalmol.* 2009;127(9):1168-1174.
19. Lakshminarayanan V. Visual acuity. In: Chen J, et al. (eds). *Handbook of Visual Display Technology.* Vol. 1. Springer-Verlag Berlin Heidelberg; 2012; pp.93-99.
20. American Academy of Ophthalmology. What is the difference between direct and indirect ophthalmoscopy? Available at: <https://www.aao.org/eye-health/ask-ophthalmologist-q/what-is-difference-between-direct-indirect-ophthal> (accessed July 2023).
21. EyeWiki. Geographic atrophy. Available at: [https://eyewiki.aao.org/Geographic\\_Atrophy](https://eyewiki.aao.org/Geographic_Atrophy) (accessed July 2023).
22. Townsend WD. *Optom Clin.* 1992;2(3):127-144.
23. Ferguson LR, et al. *PLoS One.* 2014;9(10):811203.
24. American Academy of Ophthalmology. What is optical coherence tomography? Available at: <https://www.aao.org/eye-health/treatments/what-is-optical-coherence-tomography> (accessed July 2023).
25. Buschmi E, et al. *Clin Ophthalmol.* 2015;9:563-574.
26. Chakravarthy U, et al. *BMJ.* 2010;340:c981.